

Gossypiboma; As A Case of Intestinal Obstruction

SADAF ISHAQUE, KHALID JAVEED ABID, SANA ANWER

SUMMARY:

Gossypiboma or textiloma is used to describe a retained surgical swab in the body after an operation. Inadvertent retention of a foreign body in the abdomen often requires another surgery⁽¹⁾. This increases morbidity and mortality of the patient, cost of treatment, and medicolegal problems. We are reporting case of a 30-year-old woman who was referred from periphery with acute pain in abdomen. She had a surgical history of C -section 2 months back, performed at another hospital. On clinical examination and investigation, an abdominal mass was suspected. That is a retained surgical sponge mass further confirmed by abdominal computerized tomography (CT). During laparotomy, there was found retained surgical gauze that confirmed the diagnosis of gossypiboma.

Keywords: Complication, gossypiboma, retained foreign body, textiloma

INTRODUCTION

A surgical sponge is the most common type of retained foreign body (RFB). The condition is sometimes called gossypiboma, derived from the Latin *gossypium* (cotton) and the *boma* (tumor or growth)¹. Two usual responses lead to the detection of a retained sponge. The first type is an exudative inflammatory reaction with the formation of an abscess and usually leads to early detection and surgical removal. The second type is aseptic with a fibrotic reaction to the cotton material and development of a mass.

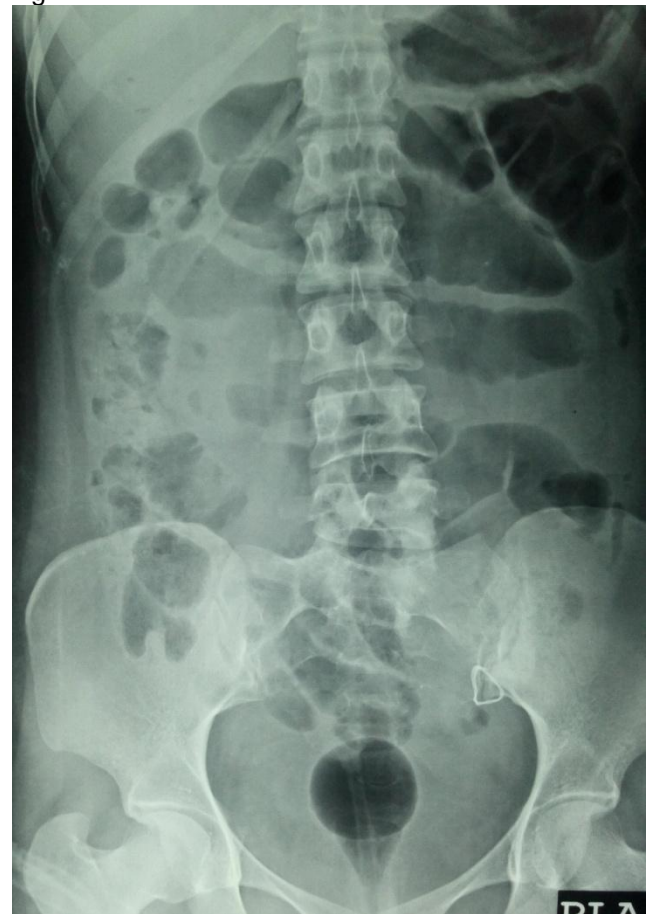In the abdomen the sponge can be surrounded by omentum and intestines, which attempt to encapsulate it. The exerted pressure and irritation on the bowel loops can lead to necrosis of the intestinal wall and the sponge erodes partially or entirely into the lumen of the bowel. This process can lead to obstruction or fistula. Patients develop symptoms of abdominal pain, nausea, vomiting, anorexia, and weight loss resulting from obstruction or a malabsorption type syndrome caused by the multiple intestinal fistulas or intraluminal bacterial overgrowth².

CASE PRESENTATION

A 30-year-old lady presented with discomfort in peri umbilical area since two months ago severity of pain abdomen increased 7 days back which was associated with increasing constipation. The only positive point in her previous history was a cesarean section 2 months back. Vital signs were normal. On abdominal examination, a round mobile mass was palpable. All routine lab data were normal. Abdominal

X-ray and barium enema was in favor of retained sponge (Fig.1,2). CT scan confirmed the diagnosis (Fig.3). Exploratory laparotomy revealed an encapsulated sponge surrounded by omentum, which was removed (Fig. 4,5,6). Postop course was uneventful.

Fig.1



Department of Surgery, Shalamar Hospital, Lahore
Correspondence to Dr.Sadaf Ishaque, Senior Registrar
Email: dr.sadafch@gmail.com Cell:03344512939

Fig. 2

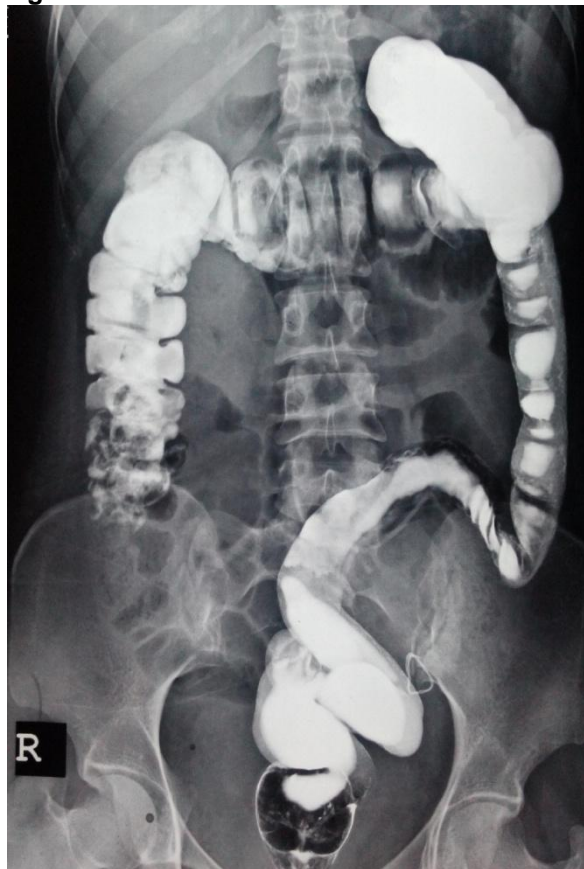

Fig.3:

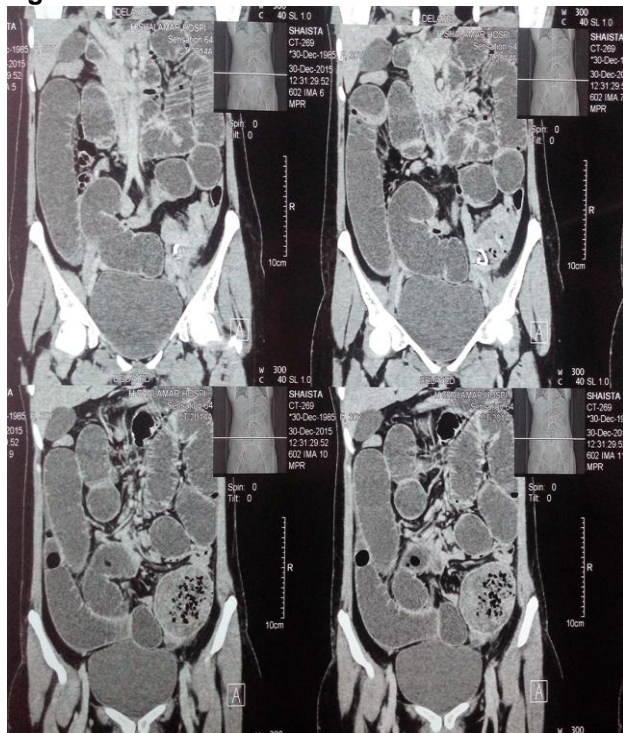


Fig.4:

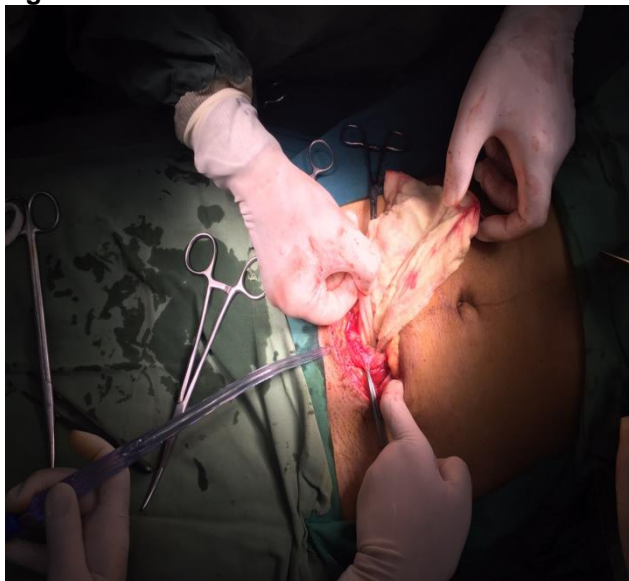
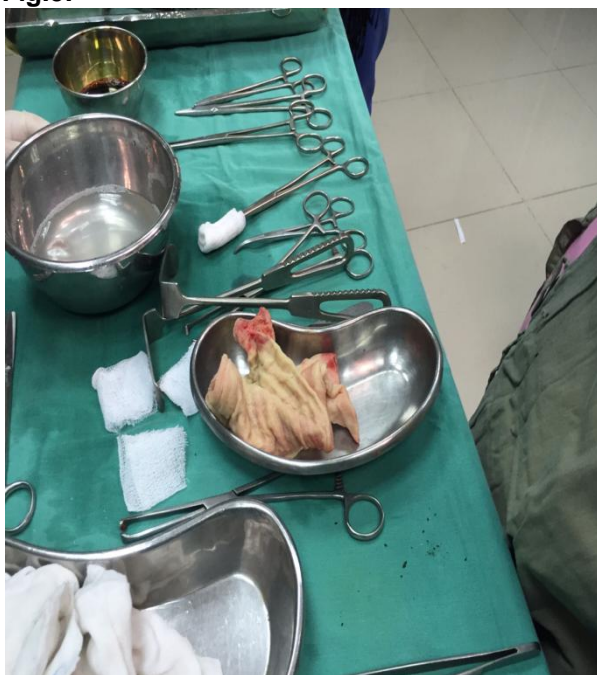
Fig.5:



DISCUSSION

An acute surgical abdomen is one of those cases in which a patient needs emergent evaluation, treatment and likely requires emergent operative treatment. The causes can be mesenteric ischemia, appendicitis, cholecystitis, diverticulitis, bowel obstruction etc. An adult patient with an acute abdomen generally appears ill and has abnormal findings on physical examination. There can be upper and lower gastrointestinal (GI) signs and symptoms with signs of peritonitis. Management includes

conservative treatment to surgical removal of definitive cause³. Gossypiboma cases generally have subacute or chronic presentation that is different from rest of the cases of acute abdomen.

This case is an important pearl to revisit the gossypiboma/retained postoperative foreign body (RFP). The gossypiboma cases can lead to embarrassment, humiliation, job loss, and law suit worldwide. It is difficult to recognize a gossypiboma by using radiological screening if the sponge does not have any radiological marker on itself, because the cotton can simulate hematoma, granulomatous process, abscess formation, cystic masses or neoplasm.

The possibility of a retained foreign body should be in the differential diagnosis of any postoperative patient who presents with pain, infection, or palpable mass. The low index of suspicion is due to rarity of the condition and latency in the manifestation. If the diagnosis is made early, laparoscopic retrieval may be feasible⁴. According to recent review article by Wan *et al.*, about retained sponges, gossypibomas were most commonly found in the abdomen (56%), pelvis (18%), and thorax (11%). The most common detection methods were computed tomography (61%), radiography (35%), and ultrasound (34%). Pain/irritation (42%), palpable mass (27%), and fever (12%) were the leading signs and symptoms, but 6% of cases were asymptomatic. Complications included adhesion (31%), abscess (24%), and fistula (20%). Average discovery time equalled 6.9 years with a median (quartiles) of 2.2 years (0.3-8.4 years)⁵. In the case report which was conducted by Sumer *et al.*, gossypiboma was extracted from the abdominal cavity 23 years after caesarean operation. This is the longest time in the literature for foreign body⁶.

The possible causes of sponge retention are emergency surgery, unexpected change in the surgical procedure, disorganization (e.g. poor communication), hurried sponge counts, long operations, unstable patient condition, inexperienced staff, inadequate staff numbers, and obesity. Most cases occurred when the sponge count was falsely pronounced correct at the end of surgery⁷. Gossypiboma most commonly occurs after gynecological and upper abdominal emergency surgical procedures, but it may also follow thoracic, orthopedic, urological, and neurosurgical procedures. Because the symptoms of gossypiboma are usually nonspecific and may appear years after surgery, the diagnosis of gossypiboma usually comes from imaging studies and a high index of suspicion.

The clinical presentation of gossypiboma is variable and depends on the location of the sponge and the type of reaction. There are two types of foreign body reactions in pathology: an exudates

reaction leading to abscess formation like our case and chronic internal or external fistula formation. Another is an aseptic fibrinous reaction resulting in adhesion, encapsulation, and eventual formation of granuloma. The latter usually presents much later than exudates reaction sequelae. They usually remain asymptomatic or present with pseudotumor syndrome. Common symptoms and signs of gossypiboma are abdominal distension, ileus, tenesmus, pain, palpable mass, diarrhea, abscess, and fistula formation, nausea, vomiting, anorexia, and weight loss resulting from obstruction or a malabsorption type syndrome caused by the multiple intestinal fistulas or intraluminal bacterial overgrowth. Retained surgical sponges can cause serious consequences, such as bowel or visceral perforation, obstruction or fistula formation, sepsis or even death. Intraabdominal gossypibomas can migrate into the ileum, stomach, colon or bladder without any apparent opening in the wall of these luminal organs⁸.

The inflammatory granulomatous reaction is the most likely cause of the extraosseous accumulation of technetium-99m-methylene diphosphonate (Tc-99m MDP) in gossypibomas as studied by nuclear medicine study⁹. Recently, New England Journal of Medicine published an article about risk factors of retained foreign bodies (RFBs). Of the 8 risk factors, the authors identified only 3 (emergency surgery, unplanned change in the operation, and body mass index [BMI]) were found to be statistically significant by multivariate logistic regression. The counting of sponges and instruments was not a significant predictor¹⁰.

The most impressive imaging finding of gossypiboma is the curved or banded radio-opaque lines on plain radiograph. The ultrasound feature is usually a well-defined mass containing wavy internal echogenic focus with a hypoechoic rim and a strong posterior shadow¹¹. On CT, a gossypiboma may manifest as a cystic lesion with internal spongiform appearance with mottled shadows as bubbles, hyperdense capsule, concentric layering, and mottled shadows as bubbles or mottled mural calcifications¹². Magnetic resonance imaging (MRI) features of gossypiboma in the abdomen and pelvis, which include the delineation of a well-defined mass with a peripheral wall of low signal intensity on T1- and T2-weighted imaging, with whorled stripes seen in the central portion and peripheral wall enhancement after intravenous gadolinium administration on T1-weighted imaging.

Prevention of gossypiboma can be done by simple precaution like keeping a thorough pack count and tagging the packs with markers. Newer technologies are being developed that will hopefully

decrease the incidence of RFP, like radiofrequency chip identification (RFID) by barcode scanner. The overall objective of this system would be to eliminate errors in the sponge count by removing the human error factor. Furthermore, the sponge count protocol itself has been implicated as a hazard to patient safety¹³.

CONCLUSION

Present case is an important pearl that one must be aware of the risk factors that could lead to a gossypiboma and take measures to prevent it. Gossypibomas are uncommon, mostly asymptomatic, and hard to diagnose. Particularly, chronic cases do not show specific clinical and radiological signs for differential diagnosis. It should be included in the differential diagnosis of soft-tissue masses detected in patients with a history of a prior operation.

REFERENCES

1. Rajput A, Loud PA, Gibbs JF, Kraybill WG. Diagnostic challenges in patients with tumors: Gossypiboma (foreign body) manifesting 30 years after laparotomy. *J Clin Oncol*. 2003;21:3700–1. [PubMed]
2. Andronic D, Lupaşcu C, Târcoveanu E, Georgescu S. [Gossypiboma--retained textile foreign body] *Chirurgia (Bucur)* 2010;105:767–77. [PubMed]
3. Uluçay T, Dizdar MG, SunayYavuz M, Aşirdizer M. The importance of medico-legal evaluation in a case with intraabdominal gossypiboma. *Forensic Sci Int*. 2010;198:e15–8. [PubMed]
4. Uranos S, Schauer C, Pfeifer J, Dagcioglu A. Laparoscopic removal of a large laparotomy pad forgotten in situ. *Surg Laparosc Endosc*. 1995;5:77–9. [PubMed]
5. Wan W, Le T, Riskin L, Macario A. Improving safety in the operating room: A systematic literature review of retained surgical sponges. *Curr Opin Anaesthesiol*. 2009;22:207–14. [PubMed]
6. Sümer A, Carparlar MA, Uslukaya O, Bayrak V, Kotan C, Kemik O, et al. Gossypiboma: Retained surgical sponge after a gynecologic procedure. *Case Report Med*. 2010;2010:1–3. [PMC free article] [PubMed]
7. Sun HS, Chen SL, Kuo CC, Wang SC, Kao YL. Gossypiboma-retained surgical sponge. *J Chin Med Assoc*. 2007;70:511–3. [PubMed]
8. Moslemi MK, Abedinzadeh M. Retained Intra-abdominal Gossypiboma, five years after bilateral orchiopexy. *Case Report Med*. 2010;2010:420357. [PMC free article] [PubMed]
9. Thomas BG, Silverman ED. "Focal uptake of Tc-99m MDP in a gossypiboma" *Clin Nucl Med*. 2008;33:290–1. [PubMed]
10. Gawande AA, Studdert DM, Orav EJ, Brennan TA, Zinner MJ. Risk factors for retained instruments and sponges after surgery. *N Engl J Med*. 2003;348:229–35. [PubMed]
11. Zappa M, Sibert A, Vullierme MP, Bertin C, Bruno O, Vilgrain V. Postoperative imaging of the peritoneum and abdominal wall. *J Radiol*. 2009;90:969–79. [PubMed]
12. Murphy CF, Stunell H, Torreggiani WC. Diagnosis of gossypiboma of the abdomen and pelvis. *AJR Am J Roentgenol*. 2008;190:W382. [PubMed]
13. Kim CK, Park BK, Ha H. Gossypiboma in abdomen and pelvis: MRI findings in four patients. *AJR Am J Roentgenol*. 2007;189:814–7. [PubMed]
14. Macario A, Morris D, Morris S. Initial clinical evaluation of a handheld device for detecting retained surgical gauze sponges using radiofrequency identification technology. *Arch Surg*. 2006;141:659–62. [PubMed]